

# BURN

## Early Excision And Skin Allograft Helps To Control Infection In Major Burn At Burn Unit Cipto Mangunkusumo Hospital

Ratna Rayeni Natasha, Aditya Wardana

Jakarta, Indonesia

**Backgrounds:** Burns are systemic complex injuries following an exposure to thermal energy and can cause damage to the skin. Skin, as body cover, will protect the underlying tissue from infection, act as a thermo regulator and control the evaporations. The principle of burn therapy is to remove the necrotic tissue and to replace the function of the skin in the body by using a temporary cover with synthetic dressings or skin allograft. Skin allograft remains an ideal temporary cover, particularly when sufficient autograft skin is not available.

**Patients and Methods:** We performed early excision and cover the wound with cadaver skin allograft in two patients suffered from major burn admitted to Cipto Mangunkusumo Hospital in 2012. We observed the wound clinically and monitored the leukocytes count to evaluate the rate of infection.

**Results:** We observed four patients with major burn. Two patients treated with early excision and skin allograft has decreasing in exudates production, less bad odor in wound area, body temperature stable in normal value and also the decreasing leukocytes counts gradually. The results of wound area and body temperature in two patients treated conventionally are not much different from the initial wound and have high leukocytes count more than 10.000 in the majority of laboratory findings. The skin allograft can control the infection by suppressing the bacterial proliferation, promote epithelialization and prepare the wound better.

**Summary:** Patient in this study treated with early excision and skin allograft has better outcome compared to patients treated conservatively.

**Keywords:** *major burn, early excision, skin allograft*

**Latar Belakang:** Luka bakar merupakan trauma sistemik yang kompleks akibat paparan energi panas dan dapat menyebabkan kerusakan pada kulit. Kulit, sebagai penutup tubuh, akan melindungi jaringan di bawahnya dari infeksi, berperan sebagai pengatur suhu dan evaporasi. Prinsip terapi luka bakar adalah membuang jaringan nekrotik dan mengganti fungsi kulit dengan penutup sementara menggunakan balutan berbahan sintesis atau kulit allograft. Kulit allograft merupakan penutup sementara yang ideal, terutama saat tidak tersedia kulit autograft.

**Pasien dan Metode:** Kami melakukan eksisi dini dan menutup luka dengan kulit allograft kadaver pada dua pasien luka bakar berat yang datang ke Rumah Sakit Cipto Mangunkusumo di tahun 2012. Kami mengobservasi luka secara klinis dan memonitor kadar leukosit untuk mengevaluasi tingkat infeksi.

**Hasil:** Kami mengobservasi empat pasien luka bakar berat. Dua pasien diterapi dengan eksisi dini dan kulit allograft menunjukkan produksi eksudat dan bau yang berkurang, suhu tubuh stabil di nilai normal dan penurunan angka leukosit secara bertahap. Sementara area luka pada dua pasien yang diterapi secara konvensional tidak banyak berbeda dengan luka saat awal, dan memiliki angka leukosit yang tinggi, yaitu di atas 10.000. Kulit allograft dapat mengontrol infeksi dengan menekan proliferasi bakteri, merangsang epitelisasi dan mempersiapkan luka dengan lebih baik.

**Ringkasan:** Pasien di dalam studi ini diterapi dengan eksisi dini dan kulit allograft memiliki hasil yang lebih baik dibandingkan dengan pasien yang diterapi secara konservatif.

**Kata Kunci:** *major burn, early excision, skin allograft*

Burns are one of the most devastating conditions encountered in medicine, it caused by thermal injury that occurs as one result of an energy transfer from a heat source to the body. The injury represents an

assault on all aspects of the patient that cause damage to many organs in the body. The skin is one of the largest organs in the body that firstly damage due to burn.<sup>1,2</sup> The skin protects us from invasive infection by preventing

*From the Burn Unit, Division of Plastic Reconstructive, and Aesthetic Surgery University of Indonesia Cipto Mangunkusumo Hospital, Jakarta, Indonesia.  
Presented in 16th IAPS Scientific Meetings In Sibolangit, North Sumatra, Indonesia*

**Disclosure:** *The authors have no financial interest to disclose.*

penetration of microorganisms into the subdermal tissues.<sup>2</sup> Risk of wound infection and systemic sepsis increases significantly with larger burn body surface areas. The principle of burn therapy is to remove the necrotic tissue and to replace the function of the skin in the body by using a temporary cover with synthetic dressings or skin allograft. Limited availability of non-injured skin for autografting full-and partial thickness wounds and slow epithelialization of skin donor sites impose major risks for survival, and they contribute to long hospital stays. The therapy of the burn patient has made notable progress with the introduction of early tangential excision and, in some cases, deep excision.<sup>3</sup> This is the part when allograft takes place. Allograft skin remains an ideal temporary cover for extensive or excised cutaneous or soft tissue wounds. Allograft skin represents the “gold standard” for biologic dressings employed for temporary wound closure.<sup>4,5</sup>

From the statistical data in the year of 2009–2010 taken from the medical record, the primary cause of death in burn patients at Cipto Mangunkusumo burn unit was infection. We used to treat patients conservatively without early excision and allograft. Base on the law principle that the skin allograft is not diverse from other organ transplantation and not forbidden in Indonesia, we use this skin allograft to helps control the infection in our centre (Figure 1&2).

### PATIENTS AND METHODS

We have very limited supply of skin allograft donated from Hallym Hospital Korea that we utilize only for indicated patients, patients with high risk of infection, major burned patients with more than 50 percent or more body surface areas wound. We have 4 patients to observe, 2 patients treated with early excision and skin allograft, 2 patients treated conservatively. We compare the clinical



Figure 1. Bottled

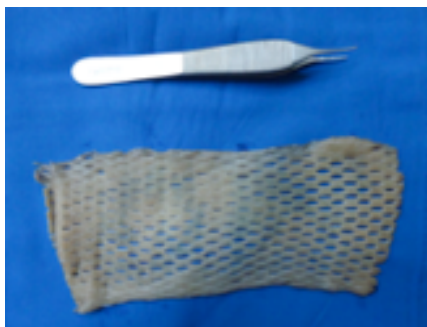


Figure 2.

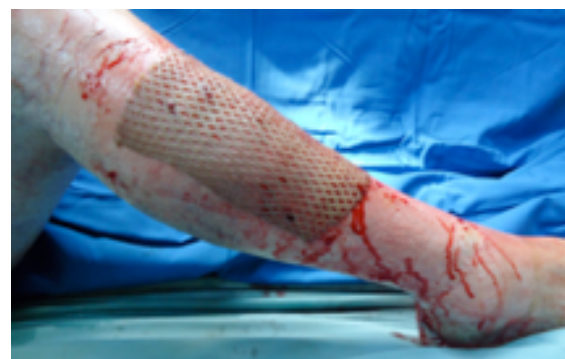

Figure 3. Example of Wound Covered by Skin

findings and laboratory findings between 2 groups.

### Case 1

A 43-year-old man, Mr.SA, suffered burns by fire over 60 percent of his body surface on March 4, 2012. Deep partial thickness burns covered 55 percent of his surface on legs, arms, trunk, neck and face. Full thickness burns covered more than 5 percent of his body surface on legs and arms. Deep partial thickness burns were excise to remove necrotic tissues and deeply enough only to obtain clean, bleeding wound bed, 1 day after admission and we covered the wound using moist and transparent dressing. On March 7, 2 days after the debridement, we excise all the full thickness wound and some of the deep partial thickness wound, the total of excision is 10 percent from the body surface area and we covered the 10 percent excised wound using the 20 x 15cm meshed banked cultured allograft (Figure 3).

### Case 2

A 35-year-old man, Mr.SB, suffered burns by fire over 65 percent of his body surface on March 19, 2012. Deep partial thickness burns covered 60 percent of his surface on legs, arms, trunk, neck and face. Full thickness burns covered more than 5 percent of his body surface on legs. On first day of admission, we performed the escharotomy to

release the tension on legs and cover it with moist and transparent dressing. Then we proceed to the 10 percent of the body surface area excision on the deep partial thickness burns to remove necrotic tissue and deeply enough only to obtain clean, bleeding wound bed, then cover it with 2 slices of 15 x 10cm meshed banked cultured allograft. We take the photograph on site when the patient just arrived to the intensive care of burn unit and having an escharotomy, since the condition of the patient fall into the critical state, we did not take any photograph and concentrate into the timeless consuming procedure in the operating theater.

### Case 3

A 29-year-old man, Mr.I, suffered deep partial thickness burns by fire over 54 percent of his body surface, December 15, 2011 on legs, arms, trunk, face and neck. This patient was treated with cleansing the wound and covered the wound using moist and transparent dressing.

### Case 4

A 44-year-old woman, Mrs.M, suffered deep partial thickness burns by fire over 47 percent of her body surface, December 5, 2011 on legs, arms, trunk, face and neck. This patient was treated with cleansing the wound and covered the wound using moist and transparent dressing as well.

**Table 1.** The Observations of Patients Treated.

No	Obsv  Patient	Odor			Exudates			Temperature			Leukocytes Count*		
		1	3	5	1	3	5	1	3	5	1	3	5
	Early Excision and Skin Allograft												
1	Mr. S. A	+++	++	++	-	-	-	36.8	37.1	36.5	10.2	6.8	10.3
2	Mr. S. B	+++	++	X	-	-	X	36.4	36.7	X	36.4	5.38	X
	Conventional Methods												
3	Mr. I	++	++	X	-	+	X	36.3	39.4	X	18.4	2.78	X
4	Mrs. M	+++	X	X	-	X	X	37.2	X	X	30.1	X	X

\* in thousand

X = death

## RESULT

We observed the wound clinically and monitored the leukocytes count to evaluate the rate of infection.

The first two patients with the early excision and allograft patients, have these following results: Mr.SA has a decrease odor in wound area on the third day of observations, have no exudates production, stable body temperature and leukocytes count. Mr.SB has a decrease odor in wound area on the third day of observations, have no exudates production, and stable body temperature. The leukocytes count decrease significantly on the third day of observation. The patient died on the fifth day of the observation.

The last two patients, the conventional therapy patients, have these following results: Mr.I has a constant odor on burn wound, have an exudates production, increasing in body temperature and have a leukocytes count drops on the third day of observations. Patient died on the fourth day of observations. Mrs.X has a wound odor, no exudates, normal body temperature, and a high leukocytes count. Patient died on the third day of observations.

## DISCUSSION

Many authors have mentioned an effort to reduce the infections rate of burn patients by removing dead tissue as one of infectious agents using early excision. In the course of time, the discovery of cadaver skin allograft is supporting the existence of such action. By combining those two, have enriched perspectives in management that is ideal for infection control in burn patients. We observed this idealism by clinical value and an objective parameter by monitoring the leukocytes count in burn patients at burn unit Cipto Mangunkusumo Hospital.

We observed four patients, all patients suffered major burns by fire over than 45 percent of the body surface area. We treated two patients with early excision and allograft, and two other patients conventionally, clean the wound and cover the wound using transparent dressing. From the observations of two patients treated with early excision and allograft, and

have higher percentage burn wound of total body surface areas have less mortality rate compared to the conventionally treated patients. They have decreasing in exudates production, less bad odor in wound area, body temperature stable in normal value and also the decreasing leukocytes counts gradually. The results of wound area and body temperature in two patients treated conservatively are not much different from the initial wound and have high leukocytes count more than 10.000 in the majority of laboratory findings. It becomes clearly that the advantage of skin allograft in the management of burn as the temporary cover. Allograft skin possesses many of the ideal properties of biologic dressings. It reduces evaporative water loss and the drainage of protein-rich fluids, prevents wound desiccation, and suppresses microbial proliferation. Wound pain is less, and is associated with better patient compliance with occupational and physical therapy. By restoring a physiologic barrier at the wound surface, it reduces heat loss through the wound and mitigates the hypermetabolic stress response to burn injury.<sup>4</sup>

## SUMMARY

Patient in this study treated with early excision and skin allograft has better outcome compared to patients treated conservatively.

**Aditya Wardhana,**  
Burn Unit, Plastic Surgery Division  
Cipto Mangunkusumo General National Hospital  
aditya\_wrdn@yahoo.com

## REFERENCES

1. Hettiaratchy S, Dziewulski P. ABC of Burns. 2004; 1-10.
2. John AD. Principles and Practice of Burns Management. Churchill Livingstone. 1996; 61-5.
3. Hector N, Federico C, Walid H. Combined Use of Allograft and Autograft Epidermal Cultures in Therapy of Burns. Plastic and Reconstructive Surgery and Burn Unit Azcapotzalco Journal. 1996. Nov; 98(6):929-39; discussion 940-1.
4. Kagan RJ, Edward D, Plessinger T. Human Skin Bank. Clin Lab Med. 2005; 587 – 605.
5. Zuijlen et al. Dermal Substitution in Acute Burns and Reconstructive Surgery: A Subjective Objective Long-Term Follow-Up. Plastic and Reconstructive Surgery Journal. 2001; 1938-46.