

Article

FLAP MODALITY FOR RESURFACING FOLLOWING EXTERNAL GENITALIA TUMOR ABLATION: A CONSECUTIVE CASE SERIES

Mufida Muzakkie¹, & Annisaa Nabila Amatullah Sakinah²

1. Plastic Reconstructive and Aesthetic Surgeon, Surgery Department - Plastic Reconstructive and Aesthetic Surgery Division, Mohammad Hoesin Central General Hospital, Faculty of Medicine, Sriwijaya University, Palembang, Indonesia.
2. General Practitioner, Surgery Department - Plastic Reconstructive and Aesthetic Surgery Division, Mohammad Hoesin Central General Hospital, Faculty of Medicine, Sriwijaya University, Palembang, Indonesia.

ABSTRACT

Introduction : External genitalia defect may result from various cases such as vulvar cancer, cervical cancer, tumor metastases, etc. Female genitalia is challenging for reconstruction due to many complex anatomical structure like urethra, vagina, anus, and its a highly mobile region. It is need to reconstruct with high successful rate and low morbidity procedure. The aim of this paper is to report various flaps for resurfacing following external genitalia defect.

Method : From September 2017 - April 2022, 7 patients referred by Obstetric Gynecology Department to Plastic Surgery Division at Muhammad Hoesin Central General Hospital. The data was reviewed retrospectively to evaluate demographic, diagnosis, choice of flap reconstruction, functional and anatomical long term evaluation.

Result : The ages of the patients ranged from 29 - 67 year-old, diagnosed with cervical cancer with tumor metastases to vulva in 16% (n=1) and vulvar carcinoma 84% (n=5). Flaps performed: Antero-lateral Thigh (ALT) flap in 14,5% (n=1), gracilis flap in 28,5% (n= 2), rotation flap in 28,5% (n= 2), keystone flap in 28,5% (n=1). A major dehiscence and need required reoperation for abscess in 16% (n=1). Flap selection based on size, region, and anatomical structure defect. ALT was chosen for wide and bilateral vulvar and perineal defect, gracilis for unilateral vulvar and perineal defect, Keystone flap for half of vulvar and perineal defect, rotation flap for defect on mons region.

Conclusion: Flap selection in genitalia external reconstruction must be consider on the anatomical loss structure and defect size to achive durable tissue for acceptable functional and mobilisation. The algorithm may help to choose for flap based on loss area.

Keywords: Genitalia external; Reconstruction; Flap.

Latar Belakang: Defek pada genitalia eksterna dapat terjadi akibat berbagai kasus seperti kanker vulva, kanker serviks, metastase tumor, dll. Rekonstruksi genitalia wanita sulit dilakukan karena banyak struktur anatomis yang kompleks seperti uretra, vagina, anus, dan daerahnya yang sangat mobile. Diperlukan rekonstruksi dengan tingkat keberhasilan yang tinggi dan morbiditas yang rendah. Tujuan dari makalah ini adalah untuk melaporkan berbagai flap untuk resurfacing setelah defek genitalia eksterna.

Metodologi: Dari September 2017-April 2022, terdapat 7 pasien yang dirujuk oleh Departemen Obstetri Ginekologi ke Divisi Bedah Plastik di Rumah Sakit Umum Pusat Muhammad Hoesin. Data ditinjau secara retrospektif untuk mengevaluasi demografi, diagnosis, pilihan rekonstruksi flap, evaluasi fungsional dan anatomi jangka panjang.

Hasil: Usia pasien berkisar antara 29 - 67 tahun, terdiagnosis kanker serviks dengan metastasis tumor ke vulva 16% (n=1) dan karsinoma vulva 84% (n=5). Flap yang dilakukan: Flap Paha Antero-lateral (ALT) 14,5% (n=1), Flap gracilis 28,5% (n= 2), Flap rotasi 28,5% (n= 2), Flap keystone 28,5% (n= 2). Dehiscence mayor dan membutuhkan operasi ulang untuk abses pada 16% (n=1). Pemilihan flap berdasarkan ukuran, regio, dan defek struktur anatomi. ALT dipilih untuk defek vulva dan perineum yang lebar dan bilateral, gracilis untuk defek vulva dan perineum unilateral, flap Keystone untuk defek setengah vulva dan perineum, flap rotasi untuk defek pada regio mons.

Kesimpulan: Pemilihan flap dalam rekonstruksi genitalia eksternal harus mempertimbangkan kehilangan struktur anatomis dan ukuran defek untuk mencapai jaringan yang tahan lama untuk fungsional dan mobilisasi yang dapat diterima. Algoritma yang dibuat dapat membantu memilih flap berdasarkan area yang mengalami defek

Kata Kunci: Genitalia eksterna; Rekonstruksi; Flap.

Conflicts of Interest Statement:

The author(s) listed in this manuscript declare the absence of any conflict of interest on the subject matter or materials discussed.

Received: 21 04 2023, Revised: 14 05 2023, Accepted: 04 06 2023

Copyright by Muzakkie, & Sakinah, (2023) | P-ISSN 2089-6492; E-ISSN 2089-9734 | DOI: 10.14228/jprjournal.v10i1.358
Published by Lingkar Studi Bedah Plastik Foundation. This is an open-access article distributed under the terms of the Creative Commons Attribution-Non Commercial-No Derivatives License 4.0 (CCBY-NC-ND), where it is permissible to download and share the work provided it is properly cited. The work cannot be changed in any way or used commercially without permission from the journal. This Article can be viewed at www.jprjournal.com

INTRODUCTION

External genitalia defect may result from various cases such as vulvar cancer, cervical cancer, tumor metastases, etc. Female genitalia is challenging for reconstruction due to many complex anatomical structure like urethra, vagina, anus, and its a highly mobile region. The surgical treatments for genitalia cancer have undergone continuous changes over the past years. Radical surgical approaches, such as block resection, have been gradually replaced in favor of surgical approaches that require dissection of less tissue to reduce postoperative morbidity and reduce genitalia deformity.¹ It is need to reconstruct with high successful rate and low morbidity procedure. Complications such as dehiscence, infections and necrosis are common after primary closure carried out following radical vulvectomy, with an increase in the hospitalization time, costs, morbidity and delay of possible adjuvant therapy.¹

Wound healing in pelvic region has historically been poor outcome, with dehiscence rates up to 66 percent and wounds persisting for a median 167 days in the absence of soft-tissue

reconstruction.² Proper wound healing occurs in three general phases, allowing the damage to heal and new tissue to replace the damaged tissue. The phases include inflammation, proliferation, and maturation. The repaired wound can be expected to obtain 80% of the original tensile strength over two years, but will not achieve the same level of pre-injury strength. Poor wound healing can occur due to the disruption of any of the three phases of healing. Common risk factors for abnormal healing include the presence of necrotic tissue, infection, ischemia, smoking, diabetes, malnutrition, glucocorticoid use, and radiation exposure.^{3,4,5}

Poor Perfusion/Ischemia - Healing wounds have an increased demand for oxygen and other factors to promote proper repair. Wounds with poor perfusion or ischemia do not receive sufficient blood flow to meet demand and are unable to heal correctly. Patient comorbidities, including vascular disease or venous insufficiency, increases patient risk for wound failure and dehiscence. Careful suturing can reduce local ischemia to the wound, preventing local wound failure.^{3,4,5}

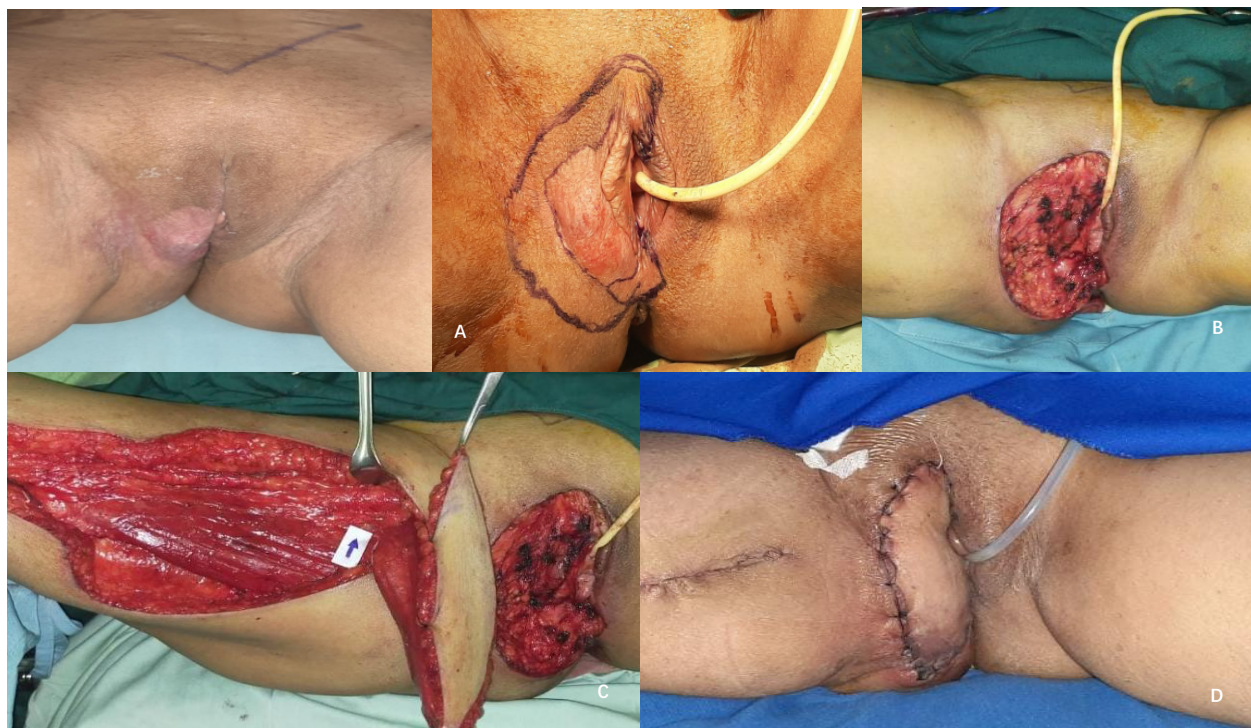

Figure 1. A 67-years old woman with basaloid squamous cell carcinoma vulva dextra (A); Unilateral vulvar (dextra) and perineum defect (B); Design and Harvesting Gracilis Myocutaneous Flap (C); Day 5 Post Operative Unilateral gracillis myocutaneous flap dextra (D)

Infection - Infected wounds are unable to heal appropriately and become 'stuck' in the inflammation phase. Without proper resolution of wound inflammation, proliferation, and maturation of the wound are unable to occur.^{3,4,5}

When dehiscence is identified, it is crucial to determine the extent of wound failure. Wound dehiscence is the separation of the margins of a closed surgical incision that has been made in skin, with or without exposure or protrusion of underlying tissue, organs or implants. Separation may occur at single or multiple regions, or involve the full length of the incision, and may affect some or all tissue layers. A dehiscent incision may, or may not, display clinical signs and symptoms of infection.⁶

The percentage of dehiscence injuries based on the type of operative procedure and location is as follows: Laparotomy 0.4%–3.8%, Cardiothoracic (sternotomy) 0.65%–2.1%, Orthopaedic surgery 1.1%–3.6%, Caesarean section 1.9%–7.6%, Oncoplastic breast reconstruction 4.6%–13.3%, Saphenous vein harvesting 8.9%, Pilonidal sinus (primary closure) 16.9–41.8%, Abdominoplasty following bariatric surgery 18.7%–21.5%.⁶

The surgical site can also increase the risk of dehiscence which can lead to infection. Proportion of dehiscent wounds lead to infection are: Abdominal dehiscence (52%–61%), Dehiscence following colorectal surgery (36,7%), Sternal incision dehiscence (49%), Episiotomy dehiscence (Up to 80%).⁶ Based on the location where there is more movement activity can increase the risk of dehiscences which has the potential for infection.⁶

The existing wound failure may be allowed to heal by secondary intention or can close secondarily. Deep dehiscence of the underlying fascia is a surgical emergency and must be closed in the operating room.⁶

To achieve primary wound healing and restore urogenital and anorectal function, the location of the defect and the presence of pelvic dead space should dictate the flap(s) selected.² In this case, we report a case series of genitalia defect cancer over a period of 5 years. This article report the demographic data, diagnosis, choice of flap reconstruction, functional and anatomical long term evaluation.

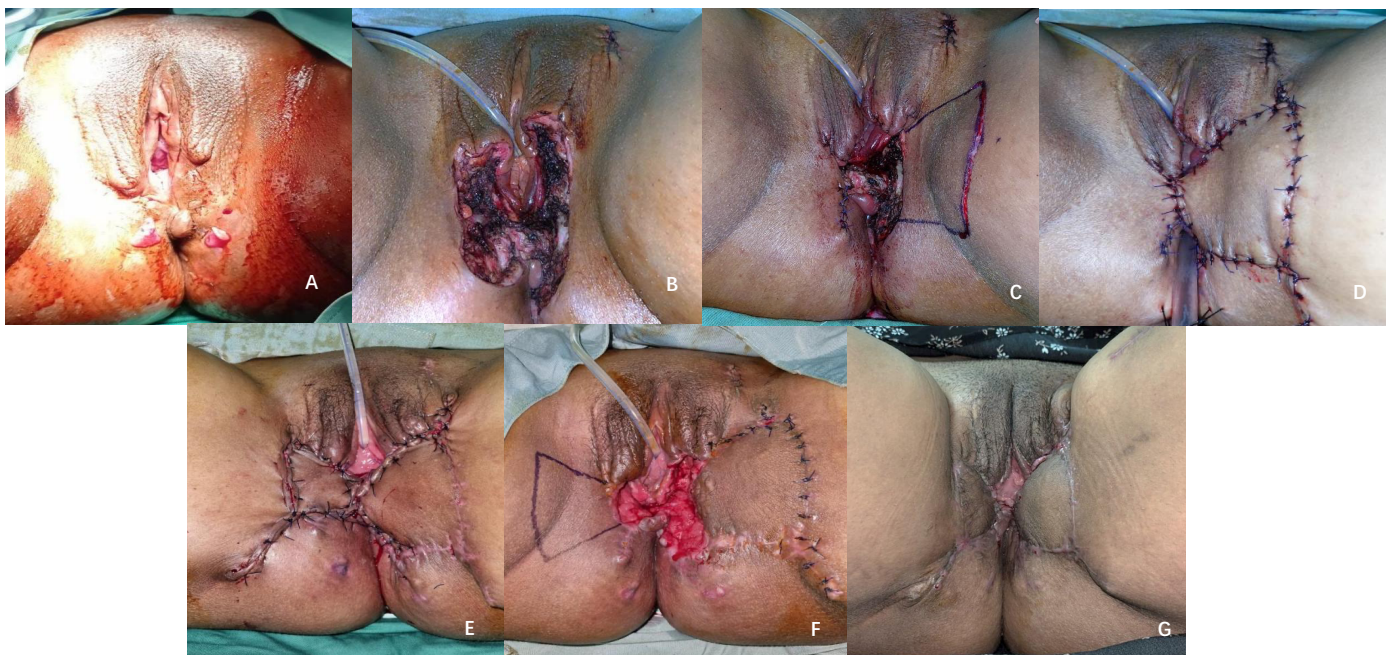

Figure 2. A 29-years-old woman with adenocarcinoma labia majora sinistra post radical vulvectomy (A); Bilateral of vulvar, a half of labia minora, left side of anal mucosa, and perineum (B); Right defect was primary suture (C); Design and Immediate pos op keystone flap in bilateral of vulvar, a half of labia minora, left side of anal mucosa, and perineum (D); Wound Dehiscence after 2 weeks post operative (E); Post operative another keystone flap at the right side (F); One month follow up after surgery (G).

METHOD

In this paper, we collect 7 case series from September 2017- April 2022, who referred by Obstetric Gynecology Department to Plastic Surgery Division at Muhammad Hoesin Central General Hospital. All patients who entered the study had obtained informed consent. The data was reviewed retrospectively.

RESULTS

Case 1

A 67-year-old woman with right vulvar carcinoma (Fig 1A). The patient underwent radical vulvectomy reconstructed with unilateral gracilis myocutaneous flap. The defect size 12 cm x 5 cm in right vulvar and perineal area (Fig 1B). Gracilis vessel and medial femoral circumflex vessels as a pedicle was identified (Fig 1C). Flap was harvested, rotated and inset to vulvar and perineal defect. In the post-operative period, there were slight bluish in distal part of the flap at perineal area (Fig 1D) but not became necrosis or dehiscence. The patient was discharged on postoperative day 10.

Case 2

A 29-years-old woman with adenocarcinoma of left labia majora (Fig 2A), performed left lymph node resection and radical vulvectomy (Fig 2B) resulted defect size 6 cm x 10 cm in bilateral of vulvar, a half of labia minora, left side of anal mucosa, and perineum (Fig 2B). The right-side defect was performed primary suture, then The Keystone Flap was performed for left side defect closure due its a curvilinear-shaped, trapezoidal design flap, which essentially comprises two conjoined V-Y flaps in opposing directions.

The design must be elliptic, with the axis parallel to the skin nerves, veins, arteries and perineum (Fig 2C). The Keystone flap half of labia minora, anal mucosa and perineum (Fig 2D).

Two weeks after surgery, patient came with dehiscence in bilateral vulva and performed revision with another keystone flap from left side (Fig 2E and 2F). One month after surgery, there is no complication, with normal micturition and flap is in good condition (Fig 2G).

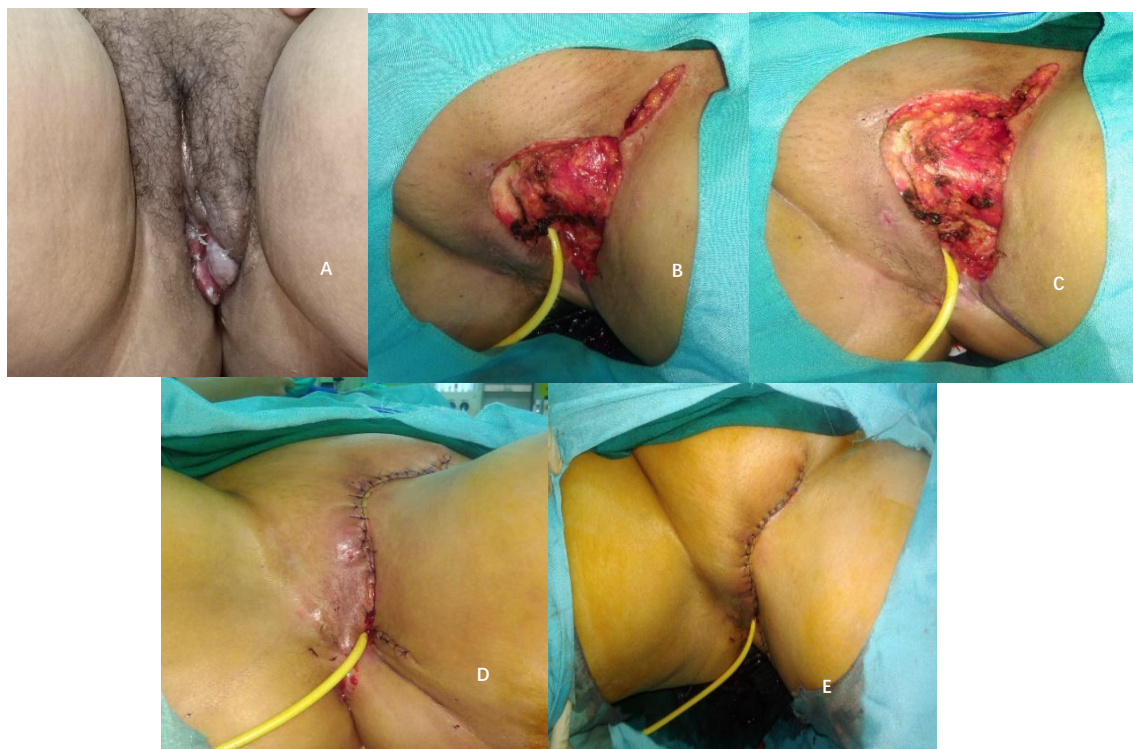

Figure 3. A 47-years-old woman with carcinoma cervix residif (a large defect) (A, B); Post operative rotation flap (C).

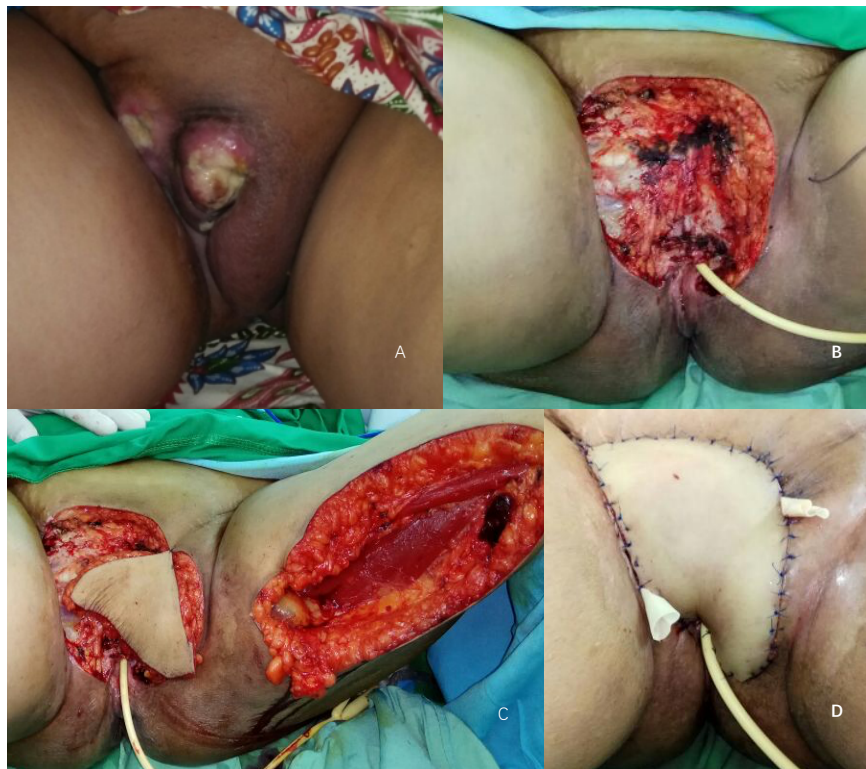

Figure 4. A 54-years-old woman with ca vulva post radical vulvectomy (A); Design and bilateral vulvar, urethra and perineal area (without anus mucosa) (B); Harvesting Gracilis Myocutaneous Flap and interpolate to defect (C); Post operative Gracillis Myocutaneous Flap (D).

Case 3

A 47-years-old woman with Cervix Carcinoma recurrent metastases to Vulvar (Fig 3A, B). Patient was performed left inguinal lymph node resection and radical vulvectomy resulting defect size 11 cm x 6 cm including left vulva and mons. Rotation flap was chosen for defect closure. Rotation of the flap across the midline is usually possible for a distance of 2 to 3 cm (fig 3C).

In the case of a large genitalia external defect need rotational flap (Fig. 3C). When this is done, an inferior base should be used for the second flap for the same reasons that were given above for this design.

In the post-operative period, the condition of the patient was stable. Postoperative hematoma is usually successfully prevented by the use of continuous suction. Catheter left in place under the flap for 2 full weeks.

Case 4

A 42-year-old woman with vulvar carcinoma was performed vulvectomy with defect size 10 x 7 cm, rotation flap was chosen for

defect closure. Rotation flaps are useful when the proposed donor site of the flap is the lateral aspect of the area. These flaps are advantageous because they have a particularly wide base and thus have an excellent blood supply. The disadvantages are, they may require relatively extensive cutting beyond the defect to develop the flap, thus increasing the risk of nerve damage as well as bleeding.

There was no flap necrosis or wound dehiscence. The patient was discharged on postoperative day 7. Later, she was free from pain, no bleeding, had normal micturition, and fluid discharge had stopped completely.

Case 5

A 54-years-old woman with vulvar carcinoma was performed radical vulvectomy (fig 4A). To reconstruct this defect, unilateral gracilis myocutaneous flap was performed (fig 4B and 4C), including gracilis artery and medial femoral circumflex vessels as a pedicle. The patient has defect size 18 cm x 15 cm in bilateral vulvar, urethra and perineal area (without anal mucosa).

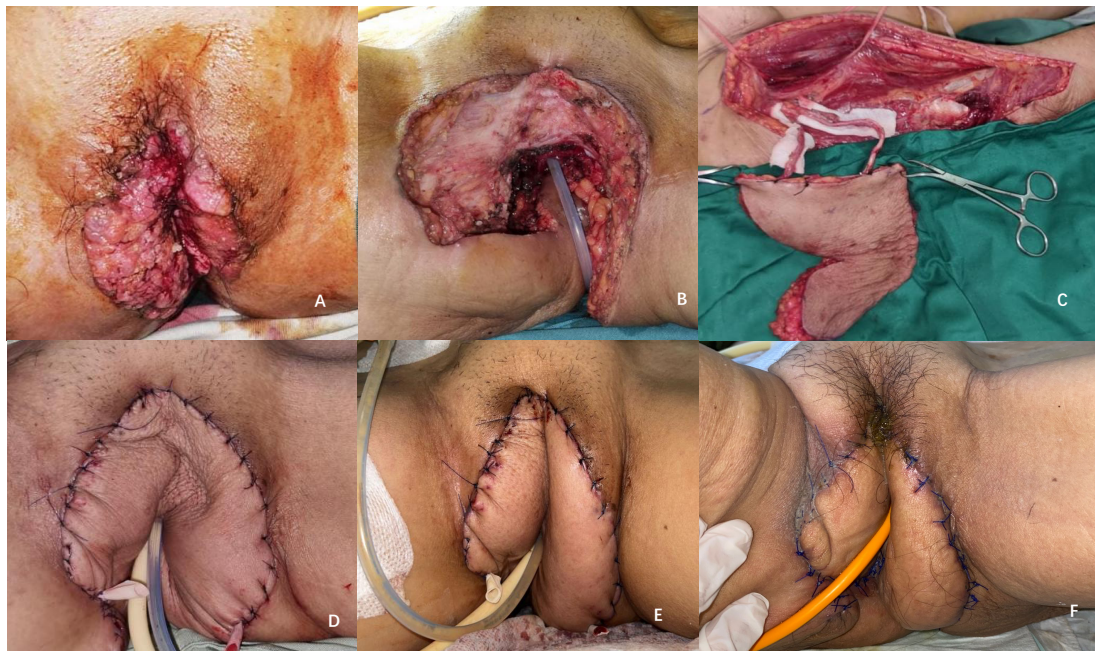

Figure 5. A 58-years-old woman with carcinoma vulva, with ALT flap (A); Defect after radical vulvectomy (B); Harvesting pedicled ALT flap (C); ALT flap in setting (D); One week after surgery (E); One month after surgery (F).

The gracilis flap can be rotated either anteriorly or posteriorly within a wide arc of rotation, allowing the flap to be inset for anterior vulvar or groin reconstruction, neovaginal formation, and repair off (fig 4C). Posterior vulvar and perineal defects. The arc of rotation of the classic flap is around the mobilized dominant vascular pedicle, while the short flap is rotated around the origin of the muscle from the pubic tubercle.

In the post-operative period, the condition of the patient was stable. Postoperatively, a minor surgical-site infection was treated conservatively (fig 4D). There was no flap necrosis or wound dehiscence. The patient was discharged on postoperative day 14. Three months later, she was free from pain, had normal

micturition, and fluid discharge had stopped completely.

Pedicled ALT flap is indicated for reconstruction of extremely large, full-thickness defects. The pivot point of the pedicled ALT flap is approximately 2 cm below the inguinal ligament on the femoral artery and correlates with the origin of the lateral circumflex femoral artery, which supplies the cutaneous perforators to the ALT flap. (Fig 5C).

In the post-operative period, the condition of the patient was stable, flap viable and catheter left in place under the flap for 1 weeks (Fig 5D, 5E). There was no flap necrosis or wound dehiscence. Three months later, she was free from pain, and had normal micturition.

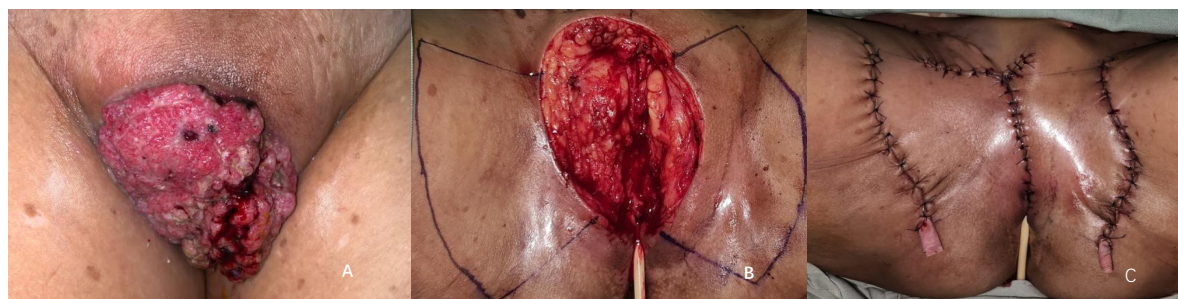


Figure 6. A 68-years-old woman with ca vulva post radical vulvectomy (A); Defect and Design Keystone Flap place under the flap for 2 full weeks (B); Immediate post operative (C).

Case 7

A 68-years-old woman with vulvar carcinoma performed radical vulvectomy (fig 6A). To reconstruct this defect, bilateral keystone flap was chosen, including medial femoral circumflex vessels as a pedicle (fig 6B). The patient has irregular shape with defect size 10 cm x 7 cm in bilateral vulvar, urethra and mons pubis (without anus mucosa). The flap inset is then given with sutures beginning from the defect end. Double flaps on both the sides of the defect can be utilized to cover larger defects or where there is less laxity of adjacent skin (Fig 6C). In the post-operative period, the condition of the patient was stable.

Postoperatively, a minor surgical-site infection was treated conservatively. There was no flap necrosis or wound dehiscence. The patient was discharged on postoperative day 10.

The results are summarized in Table 1. Seven women underwent consecutive pelvic reconstruction. The ages of the patients ranged from 29 - 67-year-old, diagnosed with cervical cancer with tumor metastases to vulva in 14% (n=1) and vulvar carcinoma 85% (n=6). Flaps performed: Antero-lateral Thigh (ALT) flap in 14,5% (n=1), gracilis flap in 28,5% (n= 2), rotation flap in 28,5% (n= 2), keystone flap in 28,5% (n=2).

A major dehiscence and need required reoperation for abscess in 16% (n=1). Flap

selection based on size, region, and anatomical structure defect. ALT was chosen for wide and bilateral vulvar and perineal defect, keystone flap for half of vulvar and perineal defect, gracilis flap for unilateral vulvar and perineal defect, and rotation flap for defect on mons region (Table 1).

DISCUSSION

Vulval cancer accounts for 4% of gynecological malignancies.⁷ The SEER database said 5-year survival ranges from 86% for stage I/II to 57% for stage III/IVA and finally to 17% with distant metastasis. Ninety percent of vulvar cancers are of squamous cell carcinoma (SCC), other rare histologies are melanoma, extramammary Paget's disease, Bartholin gland adenocarcinoma, verrucous carcinoma, basal cell carcinoma, and sarcoma. The first line of management vulvar cancer has evolved from primary surgical approach to chemoradiation. The surgical management has become more conservative due to the wellrecognized morbidity with radical vulvectomy.^{7,8} After the radical vulvectomy, we consider a reconstruction genitalia externa to maintain the anatomical and physiologi functional.

Reconstruction of the perineopelvic region or genitals is indicated in defects with large surface or in functionally crucial areas.

Table 1. Demographic data in seven patients underwent consecutive pelvic reconstruction (age), Flaps performed, defect location and complication post operative.

Case	Diagnosis (Age)	Flaps Performed	Size of Defect	Defect Location	Complication
1	Ca Vulva (67)	Gracilis Flap	12cm x5cm	unilateral vulvar and perineal defect	None
2	Ca Vulva (29)	Keystone Flap	6cm x10cm	half of vulvar and perineal defect	Wound Dehiscence need required reoperation
3	Ca Cervix (47)	Rotation Flap	11cm x6cm	Mons region	None
4	Ca vulva (42)	Rotation Flap	10cmx7cm	Mons region	None
5	Ca vulva (54)	Gracilis Flap	18 cm x 15 cm	unilateral vulvar and perineal defect	None
6	Ca vulva (58)	ALT Flap	18cm x16cm	Wide and bilateral vulvar and perineal defect	None
7	Ca vulva (54)	Keystone Flap	10 cm x 7 cm	half of vulvar and perineal defect	None

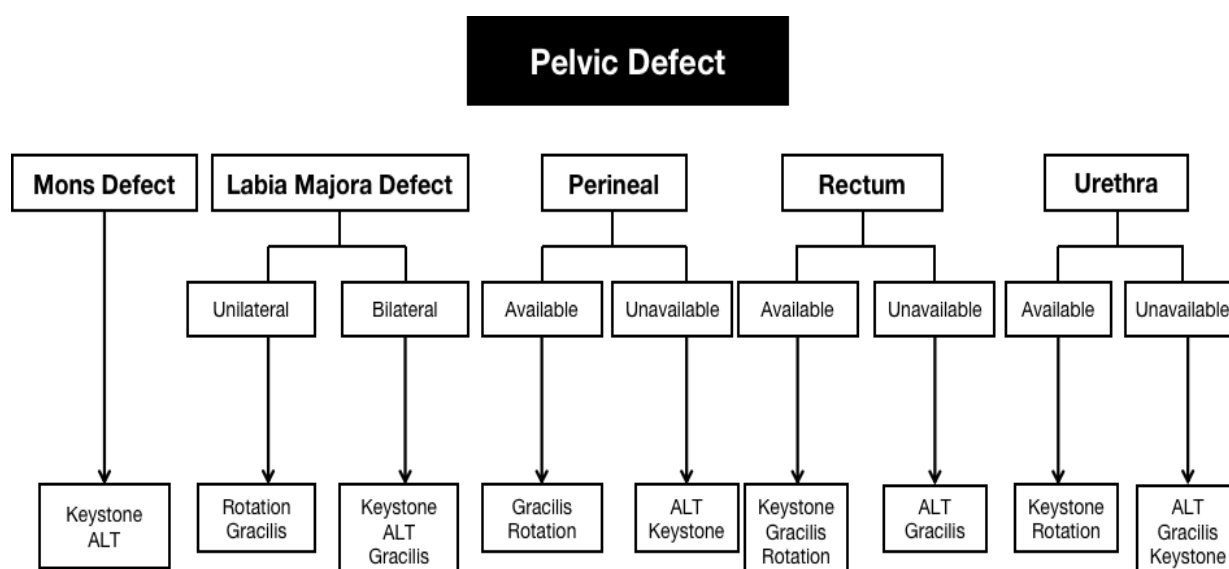


Figure 7. An Algorithmic for Resurfacing Genitalia External Defect

Reconstructive principles and challenges are mainly similar regardless of the etiology and depend more on the specific site of the defect.⁷

Intraoperative conditions are demanding due to difficult anatomy and physiology, multiple functional of organ systems, skin colonised permanently with bowel flora, external and intra-abdominal pressure and the rich vascularity with increased risk to haematoma. The patients are often multi comorbid, presenting with cardiovascular diseases, diabetes, smoking, immunosuppression and poor nutrition. These and local factors like previous radiation therapy or infection, have impact on recovery. Normal wound healing in this region is slow and often with secondary intention.^{7,8}

In several study, there is an algorithm that organized approach for the treatment of a variety of pelvic and perineal defects. In this case we discuss a flap choice for genital external defect. Pelvic defect were repaired with flap characteristic. A flap selection based on size, location, and structure anatomy of genitalia external defect. In this case series, we also developed a flap selection algorithm for external genital defects based on the defect location (fig 7).

Gracilis flap appropriate reconstructive method for medium-sized defects (measuring between 20 and 60 cm³) resulting from analrectal, vaginal, or vulvar resections, addressed to locally advanced perineal malignancies.^{9,11} Myocutaneous flaps harvested from the gracilis, gluteus maximum or rectus abdominis muscles have been considered the gold standard in vulvar

reconstruction for years. The choice between different flaps after vulvar resection seems to be strongly influenced by the location of the defect.^{9,11}

The ALT flap is a versatile flap that can be utilized in its pedicled form or as a free tissue transfer. The operator chooses to harvest it as either a fasciocutaneous or a myocutaneous flap. ALT flap was chosen for large defect with exposure of the perineum and loss of posterior vaginal wall.¹³ Double keystone flaps are designed to facilitate closure, one on either side of the defect.¹²

CONCLUSION

External genitalia defect reconstruction may be challenging for surgeon due to anatomical, functional structure, highly mobile region and recidive probability. Individual characteristic become a consideration of flap selection. A large and wide defect used to Anterolateral thigh flap. A medium sized defect used for gracilis flap. Double keystone flap used to bilateral defect. Rotation flap used to a defect with across the midline is usually possible for a distance of 2 to 3 cm. In using table and cases, we are able to discuss a minimal complication rate for a variety of defects in a complex and challenging group of patients.

Correspondence regarding this article should be addressed to:

Mufida Muzakkie. Plastic Reconstructive and Aesthetic Surgeon, Surgery Department - Plastic Reconstructive and Aesthetic Surgery Division, Mohammad Hoesin Central General Hospital, Faculty of Medicine, Palembang, South Sumatera, 30126. E-Mail: mufida.muzakkie@gmail.com

REFERENCES

1. Peiretti, M., Corvetto, E., Candotti, G., Angioni, S., Figus, A., & Mais, V. (2019). New Keystone flap application in vulvo-perineal reconstructive surgery: a case series. *Gynecologic Oncology Reports*, 100505. doi:10.1016/j.gore.2019.10050
2. Mericli, A. F., Martin, J. P., & Campbell, C. A. (2016). An Algorithmic Anatomical Subunit Approach to Pelvic Wound Reconstruction. *Plastic and Reconstructive Surgery*, 137(3), 1004–1017. doi:10.1097/01.prs.0000479973
3. Grubbs H, Manna B. StatPearls [Internet]. StatPearls Publishing; Treasure Island (FL): May 21, 2022. Wound Physiology.
4. Ozgok Kangal MK, Regan JP. StatPearls [Internet]. StatPearls Publishing; Treasure Island (FL): May 8, 2022. Wound Healing.
5. Wallace HA, Basehore BM, Zito PM. StatPearls [Internet]. StatPearls Publishing; Treasure Island (FL): Aug 25, 2022. Wound Healing Phases.
6. World Union of Wound Healing Societies (WUWHS) Consensus Document. Surgical wound dehiscence: improving prevention and outcomes. *Wounds International*, 2018
7. Bacalbasa, Nicolae; Balescu, Irina; Mereuta, Andreea; Tanase, Alina; Ghelmen, Adriana; Vilcu, Mihaela; and Brezean, Iulian (2019) "Gracilis myocutaneous flap for perineal defect reconstruction after left hemivulvectomy for locally invasive vulvar cancer – A case report and a literature review," *Journal of Mind and Medical Sciences*: Vol. 6 : Iss. 1 , Article 27. DOI: 10.22543/7674.61.P176180
8. Siegel R, Ward E, Brawley O, Jemal A (2011) *Cancer statistics, 2011*. CA Cancer J Clin 61:212–236
9. SEER Cancer Statistics Factsheets: Vulvar cancer. Bethesda, MD:National Cancer Institute, April 22, 2016
10. Strauch, B., Vasconez, LO., et al. (2009). *Grabb's Encyclopedia of Flaps. Torso, Pelvis, and Lower Extremities*. 3rd Edition.
11. Kolehmainen, M., Suominen, S., & Tukiainen, E. (2013). Pelvic, Perineal and Genital Reconstructions. *Scandinavian Journal of Surgery*, 102(1), 25–31. doi:10.1177/14574969131020010
12. Srivastav, S., Gupta, S., & Sharma, A. (2020). Keystone Flap as a Reconstructive Option for selected areas; A Prospective Study. *Journal of Clinical Orthopaedics and Trauma*. doi:10.1016/j.jcot.2020.06.019
13. Bacalbasa, Nicolae; Balescu, Irina; Mereuta, Andreea; Tanase, Alina; Ghelmen, Adriana; Vilcu, Mihaela; and Brezean, Iulian (2019) "Gracilis myocutaneous flap for perineal defect reconstruction after left hemivulvectomy for locally invasive vulvar cancer – A case report and a literature review," *Journal of Mind and Medical Sciences*: Vol. 6 : Iss. 1 , Article 27. DOI: 10.22543/7674.61.P176180
14. Shridharani, S.M. Wang, H.D. 2013. Interesting Case Series Pedicled Anterolateral Thigh Flap for Vaginal and Perineal Reconstruction. Department of Plastic and Reconstructive Surgery, The Johns Hopkins University School of Medicine, Baltimore, Md.